

# Needle assisted arthroscopic clysis of the medial collateral ligament of the knee: a simple technique to improve exposure in arthroscopic knee surgery

Xinning Li,<sup>1</sup> Ronald M. Selby,<sup>2</sup>  
Ashley Newman,<sup>3</sup> Stephen J. O'Brien<sup>3</sup>

<sup>1</sup>Division of Sports Medicine and Shoulder Surgery, Boston University School of Medicine, Boston Medical Center, MA; <sup>2</sup>Orthopaedic Surgery and Sports Medicine, New Brunswick, NJ; <sup>3</sup>Division of Sports Medicine, Hospital for Special Surgery, New York, NY, USA

## Abstract

During knee arthroscopy, narrowness and tightness maybe encountered in the medial compartment that does not allow sufficient visualization or instrumentation. When this occurs, our team has found it helpful to perform a percutaneous clysis of the deep portion of the medial collateral ligament with a spinal needle. With the knee positioned in 10° to 20° of flexion and a valgus stress is applied. A spinal needle (18 Gauge) is passed percutaneously through the medial collateral ligament between the tibial plateau and undersurface of the medial meniscus. Several passes are made with the spinal needle with the bevel of the needle angled to selectively divide the fibers while keeping the medial collateral ligament under tension. Then with controlled valgus force, the medial compartment will progressively open allowing improved visualization to the posteromedial corner of the knee. This increase in space gives an enhanced visual field and further allows more room for arthroscopic instrumentation.

## Introduction

The development of arthroscopic equipment and techniques has revolutionized the diagnosis and treatment of both acute and chronic knee conditions.<sup>1</sup> However, inadequate exposure and limited working space may predispose the articular cartilage or other structures to iatrogenic injury, prolonged operative time or suboptimal results. A frequently encountered situation along the learning curve of operative knee arthroscopy is difficulty in visualizing and/or operating in the posterior aspect of the medial knee compartment.<sup>2</sup> This may be due to soft tissue

contracture, early degenerative changes, or intrinsically tight ligaments. Various methods of posteromedial portal placement have been described to improve visualization of the posteromedial corner of the knee.<sup>3</sup> However, addition of extra arthroscopic portals may have its own intrinsic risks, which may further compromise positioning of the instruments and make either meniscal repair or resection more difficult.

The purpose of this article is to describe an arthroscopic surgical technique, which simplifies and enhances the approach to the posteromedial corner for arthroscopic visualization and arthroscopic surgery (meniscectomy, meniscus repair, etc.). We describe a simple technique that maximizes exposure of the medial knee compartment with minimum additional patient morbidity.

## Surgical technique

Our standard set up for knee arthroscopy places the patient in the supine position. The operating room table remains in a flat position. A pneumatic tourniquet is commonly used at the superior aspect of the thigh on the operative leg, but not inflated unless the need arises. A flat or round, well-padded, lateral post is positioned lateral to the tourniquet about half way up the thigh. This will allow the operating surgeon to apply controlled valgus stress to the knee while in extension which has a residual opening effect on the medial compartment. In most routine arthroscopic survey of the knee, this valgus maneuver alone will give adequate visualization and space within the posteromedial portion of the medial compartment to allow arthroscopic instrumentation. Occasionally however, narrowness and tightness is encountered and this maneuver alone does not allow sufficient space and separation between the tibial plateau and femoral condyle for adequate visualization and access for surgery in this particular location. When this situation is encountered, we find it helpful to perform a percutaneous clysis of the deep portion of the medial collateral ligament utilizing an 18 gauge spinal needle.

This technique is performed in the following manner, the operating surgeon stands between the foot of the operating room table and the patient's extended leg, holding the patient's ankle just above his (the operating surgeon's) iliac crest. The patient's foot is secured behind the surgeon in this fashion. The lateral post is fixed securely to the operating room table with a clamp and well padded with combines and web roll. The post and the tourniquet both remain under the surgical drapes and are away from the surgical field. Holding the extended lower limb in this fash-

Correspondence: Xinning Li, Division of Sports Medicine and Shoulder Surgery, Boston University School of Medicine, Boston Medical Center, 720 Harrison Street – Suite # 808, Boston, MA 02421, USA.

E-mail: xinning.li@gmail.com

Key words: medial collateral ligament, knee arthroscopy, meniscectomy, ligament release.

Contributions: the authors contributed equally.

Conflict of interests: the authors declare no potential conflict of interests.

Received for publication: 15 November 2013.

Accepted for publication: 8 December 2013.

This work is licensed under a Creative Commons Attribution NonCommercial 3.0 License (CC BY-NC 3.0).

©Copyright X. Li et al., 2013  
Licensee PAGEPress, Italy  
Orthopedic Reviews 2013; 5:e38  
doi:10.4081/or.2013.e38

ion the surgeon leans into the leg exerting a *controlled* valgus stress on the extended knee. This brings the medial collateral ligament out to length and makes it easier to palpate. In assessing the medial compartment arthroscopically, the standard arthroscopic technique for the knee is used with an anterolateral portal for viewing and anteromedial portal for instrumentation. After a standard diagnostic arthroscopy is performed, attention is then turned to the medial compartment.

To optimize the view of this compartment, the knee is positioned in 10° to 20° of flexion, the tibia is externally rotated, and a valgus stress is applied against the padded lateral post (Figure 1). With a 30-degree arthroscope viewing the medial compartment from a lateral parapatellar portal, an 18 gauge spinal needle is passed percutaneously through the medial collateral ligament and is seen to enter the joint under direct arthroscopic visualization between the tibial plateau and undersurface of the mid-body of the medial meniscus at the level of the meniscocapsular attachment (Figure 2A). Having achieved this position, several additional passes are made with the spinal needle in a sewing machine type maneuver. Care is taken not to injury the meniscus or any other structure of the knee. The bevel of the needle is then angled to partially divide these fibers while keeping the knee in 10 to 20 degrees flexion under constant and controlled valgus force against the lateral post. As the knee is held with valgus stress, the medial compartment of the knee will progressively increase which correlates to the number of cut fibers of the medial collater-

al ligament (MCL) and 18-gauge needle passes. The extra space thus obtained gives an enhanced visualization to allow more space and room (Figure 2B) for arthroscopic visualization and instrumentation.

## Discussion

Arthroscopic visualization and exposure of the posteromedial compartment of the knee can be challenging despite advances in arthroscopic equipment and technique. Warren *et al.*<sup>4</sup> have described the deep portion of the medial collateral ligament as a condensation of the medial capsule which forms a vertically oriented band of short fibers. Posteromedial meniscus lesions have been called *the Achilles heel of knee surgery* as they consistently represent the single greatest source of diagnostic errors.<sup>5-7</sup> This is particularly so in *tight knees* with overseen lesion at the periphery of the posterior horn of the medial meniscus. A cadaver study reported the arthroscopic field of view on the medial side of the knee was significantly less than the lateral side with both a 30 degree or 70 degree arthroscope. Furthermore, in 22% of all knee arthroscopy, a blind spot was present in the medial compartment of the menisco-capsular periphery.<sup>2</sup> Thijn *et al.*<sup>3</sup> found a 17% arthroscopic false negative rate for arthroscopically documented posterior longitudinal tears of the medial meniscus. In addition, 14 % of posterior horn medial meniscal tears were missed at the time of arthroscopy as determined by subsequent arthrotomy.<sup>5</sup>

Visualization of the medial compartment may be improved by a valgus, external stress to the knee as described by O'Connor.<sup>8</sup> However in the anaesthetized patient, it is important to avoid excessive force as it is possible to completely rupture the medial collateral ligament by the use of excessive valgus force to open up the medial compartment. In a series of 160 ligament injuries sustained during knee arthroscopy, a leg holder had been used in 143 cases. Allum *et al.*<sup>9</sup> in a review of knee arthroscopy complications cautions judicious use of valgus force particularly when trying to view the posterior horn of the medial meniscus in a tight compartment especially seen in a middle-aged or elderly patient in whom the soft tissues are likely to be less flexible. Furthermore, damage to the articular cartilage may occur when using either standard or powered arthroscopic instruments in a tight working space.<sup>9</sup>

The medial collateral ligament is a viscoelastic structure approximately 10 cm long and extendable by 20% during normal flex-

ion. Degenerative changes are associated with reduction of the joint space. A biomechanical study in both living and cadaveric subjects has shown a significant amount of stiffening occurring in the knee with advanced degenerative changes. Stiffness of the medial compartment was 184% greater in arthritic knees compared to non-arthritic knees. A stiffer ligament will require greater loads to produce equal lengthening than would be required in a less stiff ligament. In the MCL clysis technique described, the deep MCL is effectively lengthened with a spinal needle in a controlled manner allowing greater access to the medial compartment. Isolated sectioning of the deep medial ligament has been shown in biomechanical studies to have clinically imperceptible increase in valgus and internal rotation limits in any degree of knee flexion.<sup>10,11</sup>

While the more experienced arthroscopist may have the dexterity and experience to operate well in a tight space in the posterior portion of the medial compartment, we feel that a controlled arthroscopic medial collateral ligament clysis or release with a spinal needle is a relatively simple, straightforward maneuver which may prove helpful when a tight posterior medial compartment is encountered despite manual valgus directed forces. In particular, this can be valuable in resident education and for others learning the techniques of arthroscopy as it allows much easier access to an otherwise tight space and thereby prevents scuffing of joint cartilage surfaces and inadequate resection. In addition, the release of selected fibers of the deep medial collateral ligament has been found to add minimal or no discomfort to the patient in a postoperative period and uniformly heals with no increased excursion or laxity found in the ligament on further examination. The senior author (SJO) has used this technique repeatedly over the past 20 years and particularly in teaching residents and fellows and has experienced no complications. In general, between two to five passes of the 18-gauge spinal needle and controlled valgus force against a lateral post is necessary to open the posterior medial knee compartment to allow for adequate space to visualize the posterior meniscus and insertion of arthroscopic instrumentation (4.5 mm shaver) in a tight knee. With this technique, there were no cases of post-operative valgus instability or complications resulting in secondary surgeries. Furthermore the patients do not need to be braced in the post-operative period or require more pain medications. The technique is easy to employ and we feel that it could prove helpful for many knee arthroscopists when a tight medial space is encountered.

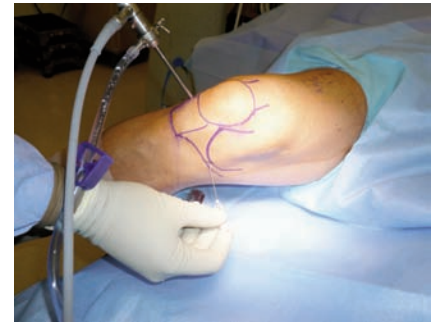

Figure 1. Outside view of spinal needle insertion as valgus force is maintained by the surgeon. View of a right knee from its medial aspect. The knee is held in near full extension while the surgeon applies controlled valgus stress by pushing his pelvis against the medial malleolus. The arthroscope (seen at the top of the picture) is viewing from the lateral parapatellar portal. The surgeon's right hand inserts the 18-gauge spinal needle at the medial aspect of the knee.

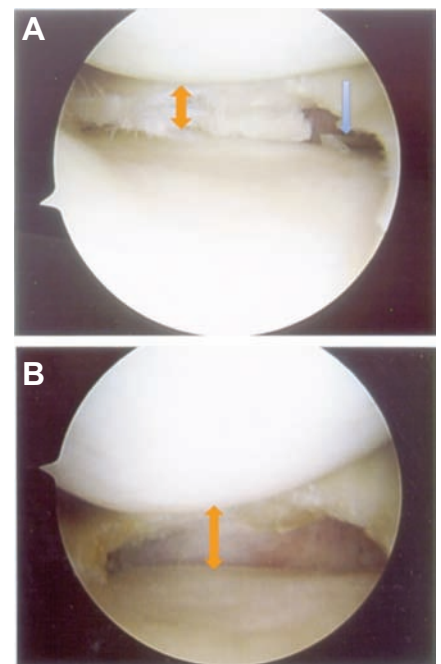


Figure 2. A) Note inside view with the arthroscope in the lateral parapatellar portal showing position of spinal needle and narrowness of joint space. With the arthroscope in the lateral parapatellar portal this view is posteromedial. The orange double arrow displays joint space opening prior to clysis. Note the spinal needle entering beneath the medial meniscus pointed out by the blue arrow on the right. B) Same view showing increase in the medial joint space following the MCL clysis and controlled release. Note the increased joint space opening (double orange arrow) showing the same arthroscopic view following clysis and completed partial meniscectomy.

## References

1. Jackson RW. History of arthroscopy. McGinty JB, Caspari RB, Jackson RW, Poehling GG, eds. *Operative arthroscopy*. New York: Raven Press; 1991. pp 1-4.
2. Morin WD, Steadman JR. Arthroscopic assessment of the posterior compartments of the knee via the intercondylar notch: the arthroscopist's field of view. *Arthroscopy* 1993;9:284-90.
3. Thijn CJ. Accuracy of double-contrast arthrography and arthroscopy of the knee joint. *Skeletal Radiol* 1982;8:187-92.
4. Warren LF, Marshall JL. The supporting structures and layers on the medial side of the knee: an anatomical analysis. *J Bone Joint Surg Am* 1979;61:56-62.
5. Gillies H, Seligson D. Precision in the diagnosis of meniscal lesions: a comparison of clinical evaluation, arthrography, and arthroscopy. *J Bone Joint Surg Am* 1979;61:343-6.
6. Ireland J, Trickey EL. Arthroscopy and arthrography of the knee. *J Bone Joint Surg Br* 1980;62B:3-6.
7. Kimori K, Suzu F, Yamashita F, et al. Evaluation of arthrography and arthroscopy for lesions of the posteromedial corner of the knee. *Am J Sports Med* 1989;17:638-43.
8. O'Connor RL. Arthroscopy in the diagnosis and treatment of acute ligament injuries of the knee. *J Bone Joint Surg Am* 1974;56:333-7.
9. Allum R. Complications of arthroscopic reconstruction of the anterior cruciate ligament. *J Bone Joint Surg Am* 2003;85:12-6.
10. Grood ES, Noyes FR, Butler DL, Suntay WJ. Ligamentous and capsular restraints preventing straight medial and lateral laxity in intact human cadaver knees. *J Bone Joint Surg Am* 1981;63:1257-69.
11. Griffith CJ, LaPrade RF, Johansen S, et al. Medial knee injury: part 1, static function of the individual components of the main medial knee structures. *Am J Sports Med* 2009;37:1762-70.